

# Esthetic Crown Lengthening for Upper Anterior Teeth: Indications and Surgical Techniques

Mohammad Assaf

Assistant Professor, Faculty of Dentistry, Al-Quds University, Jerusalem, Palestine.

Correspondence to:  
Dr. Mohammad Assaf  
Faculty of Dentistry, Al-Quds University, Jerusalem,  
Palestine  
Contact Number: 0097022791065  
Email: massaf@dentist.alquds.edu

Contact Us : editor@ijdmr.com  
Submit Manuscript : submissions@ijdmr.com  
www.ijdmr.com

## ABSTRACT

Periodontal surgery has a major role in today's esthetic dentistry. Although the classic indications of crown lengthening are to preserve the biological width, some procedures could be performed on sound teeth for esthetic reasons. Main indications for esthetic crown lengthening of anterior teeth are to expose the anatomic crown of teeth, reduce asymmetry between contralateral teeth, and to reduce the excessive gingival exposure. Different indications are illustrated with the relevant cases to explain the surgical treatment approach utilized to improve the esthetic appearance for each condition.

**KEYWORDS:** Crown lengthening, Esthetics, Gingivectomy, Gummy smile, Periodontal surgery

## INTRODUCTION

Esthetic crown lengthening may include a variety of surgical techniques, all of which aim to improve the esthetic appearance of teeth and gingiva. Such surgeries may be indicated to increase a patient's satisfaction and quality of life. As any other elective procedure, absence of dental infections or gingival inflammation is a prerequisite to all of the surgical procedures discussed in this report. Esthetic crown lengthening is not typically indicated to treat elongated teeth caused by periodontal diseases or gingival recessions. This paper discusses different situations where crown lengthening may improve the esthetic appearance of sound upper anterior teeth; indications for surgery and different surgical techniques will be explained as well.

## IDENTIFYING THE PROBLEM

There are three main scenarios of cases that could be corrected by crown lengthening for sound upper anterior teeth; however, more than one of these problems could be corrected in the same surgical procedure:

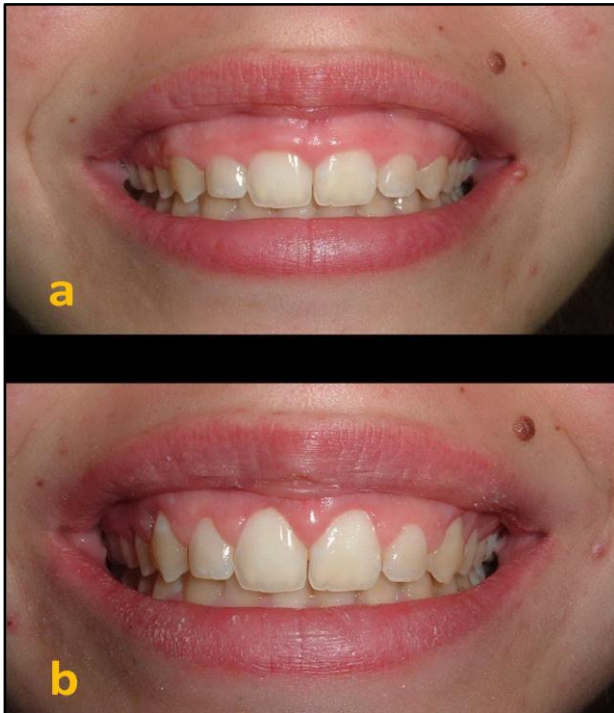1. ***Excessive gingival exposure or "gummy smile" appearance:***

This condition could be examined by extra-oral evaluation, by asking the patient to smile. The amount of exposure is relative to the position of the upper anterior teeth vis-à-vis the upper lip movement while smiling. Excessive exposure of gingiva occurs when an individual has a high lip-line. Usually a gingival exposure of more than 3 mm, apical to the gingival margin of upper teeth, could cause an unwanted "gummy smile" appearance.<sup>1</sup> An extra-oral example of a

*How to cite this article:*

Assaf M. Esthetic Crown Lengthening for Upper Anterior Teeth: Indications and Surgical Techniques. Int J Dent Med Res 2014;1(3):86-91.

patient with excessive gingival appearance due to a high lip-line is shown (Figure No.1).

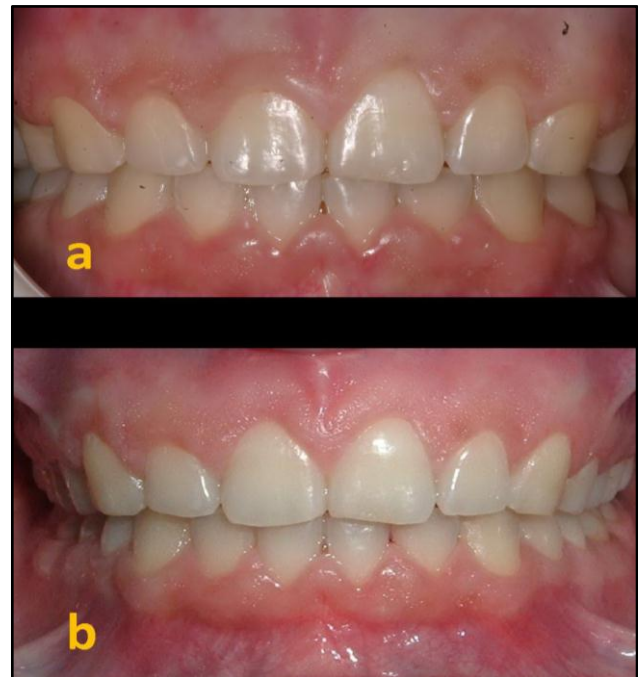

**Figure No.1.** High lip line with excessive gingival exposure;(a)before,(b) after esthetic crown lengthening.

## 2. Asymmetry of tooth length and gingival margins:

Symmetry of contralateral teeth and harmony of gingival margins of teeth gives an appearance that is comfortable to the eye. This relationship can be evaluated through intra-oral examination and compared to the ideal relationships of the gingival margins of the maxillary anterior teeth. A patient with asymmetry in tooth sizes and disharmony of the gingival margins, which has occurred during fixed orthodontic treatment, is shown (Figure No.2). In 1988, Edward P. Allen<sup>2</sup> has suggested that the ideal relationships of upper anterior teeth are achieved when: 1) The gingival margins of the central incisors are symmetric, and are either even with or 1 mm apical to the margins of the lateral incisors. 2) The gingival margins of the canines should be 1 mm apical to the level of the lateral incisors. 3) A line drawn horizontally at the level of the canine gingival margins should be parallel to the inter-pupillary line. 4) The smile should

expose a minimal amount of gingiva apical to the centrals and canines, and should be in harmony with the smile line. 5) The lateral incisors should be exposed 1.5 mm less than the length of the centrals. He also suggested that the crowns of central incisors and canines could be exposed to an overall length of 11 to 12 mm to attain the maximal gingival reduction.<sup>2</sup>



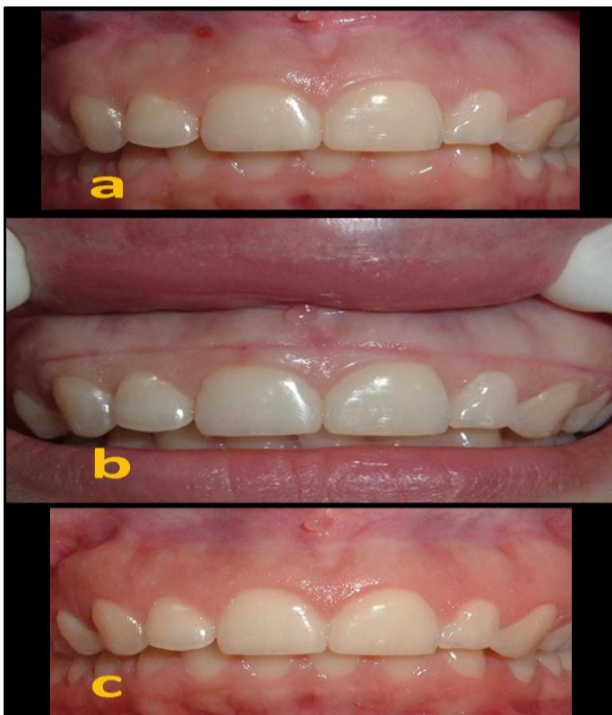
**Figure No.2.** Asymmetry of gingival margin; (a) before, (b) two months after esthetic crown lengthening.

## 3. Incomplete passive eruption or “short teeth” appearance:

Altered passive eruption may be present on all or some of the upper anterior teeth. Usually, these patients are complaining of a “gummy smile” appearance. Such patients are most of the time unaware of that they have “short teeth” till they are examined. Average lengths of anterior teeth are 11, 9, and 10.5 mm for upper centrals, laterals, and canines, respectively. A simple determination of the deficiency of length of anterior teeth could be conducted by measuring the length of the exposed crown, using a ruler or periodontal probe (Figure No.3).

To plan for the esthetic crown lengthening surgery for upper anterior teeth, a line parallel

to the inter-pupillary line is drawn connecting the anticipated buccal gingival margins of the canines and central incisors (Figure 3b). This line is supposed to meet the level of the cemento-enamel junction at the buccal surface of the canines and centrals, should be no more than 12 mm from the incisal edge of the central incisors, and no more than 11 mm from the cusp tips of the canines.<sup>2</sup> Attrition of the incisal edges of teeth needs to be compensated when estimating the level of the cemento-enamel junction of “worn” teeth.<sup>3</sup> Evaluation of the alveolar bone level is obtained by “probing to bone” or “sounding” under local anesthesia where the periodontal probe is forced through the periodontal tissues apical to the sulcus and up to the level of the alveolar bone.<sup>4</sup> Conditions associated with bone dehiscence or a thin labial osseous plate (thin, scalloped periodontium), may make identification of the alveolar crest less accurate than thicker bone. This, in retrospect, may be of less consequence since thin or dehiscid labial plates are more likely to resorb postoperatively.<sup>5</sup>

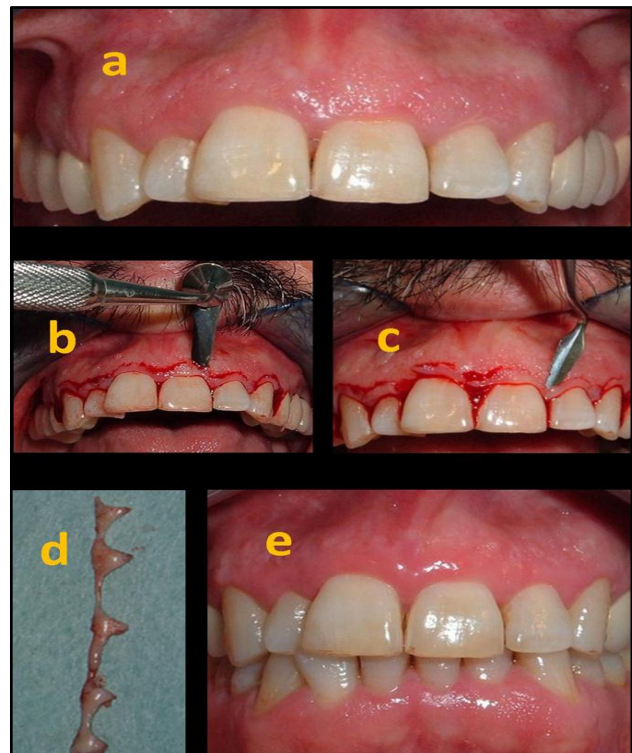


**Figure No.3:** Crown lengthening to expose the anatomic crowns; (a) before surgery, (b) line connecting anticipated gingival margins of centrals and canines, (c) after esthetic crown lengthening.

## SURGICAL TECHNIQUES

After determining the problem, the amount of planned soft resection, the extent to which bone resection might be required, and the surgical technique could be determined. If only soft tissue removal was needed (no bone resection) then there are two options; gingivectomy (beveled incision) or apically positioned flap (reverse beveled incision). If the crest of alveolar bone was less than 3 mm away from the anticipated gingival margin, then bone resection is necessary, which requires a full-thickness flap to be raised.<sup>6</sup>

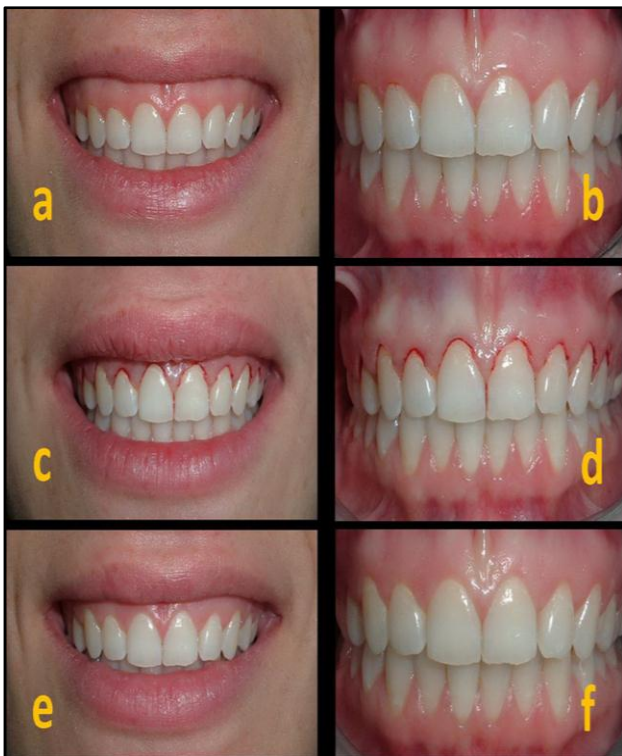Gingivectomy could be performed by surgical blades or specially designed knives as Kirkland knife and Orban knife; cutting instruments are used to make a beveled incision which is about 45 degrees towards the long axis of tooth with an apico-coronal direction (Figure 4). Some clinicians prefer to use diode laser instead of sharp instruments for gingivectomy / gingivoplasty due to its advantage of having more delicate strokes and intraoperative hemostasis.<sup>5</sup>



**Figure No.4:** Gingivectomy using (b) surgical blade and (c) Orban knife, and showing (d) the excised gingiva.

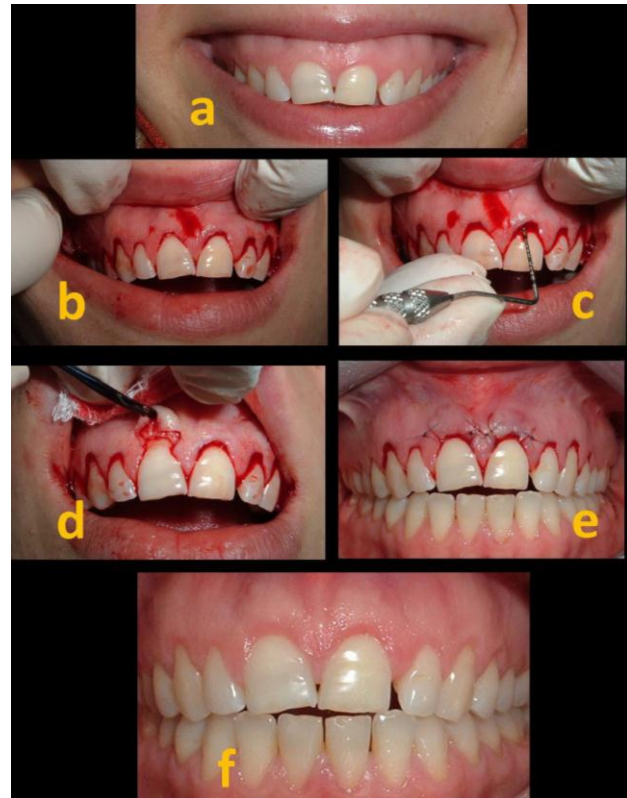


The minimal apically positioned flaps are very practical when a small amount of the labial gingival margin is to be removed and when no bone resection is needed (Figure 5). They have the advantage of safely preserving the papilla by just limiting the incision within the mesial and distal buccal line angles of the tooth (Figure 5d). Another advantage is that further bone resection could be performed immediately after the excision of the gingiva if the bone level is not distant enough from the new gingival margin (Figure 6).



**Figure No.5:** Esthetic crown lengthening using an apically positioned flap without osseous resection; (a+b) before, (c+d) immediately after excision, (e+f) six weeks post-op.

When bone resection is to be performed, the first incision will be the same as in an apically positioned flap, and excess gingiva is removed before elevation of a full thickness flap to expose the alveolar bone. Preservation of the inter-proximal papilla is a critical issue in the esthetic zone.<sup>7</sup> Thus; one option is to perform two small vertical incisions on the line angles of the tooth/teeth that need bone resection in order to raise a minimal full-thickness flap (Figure 6d).

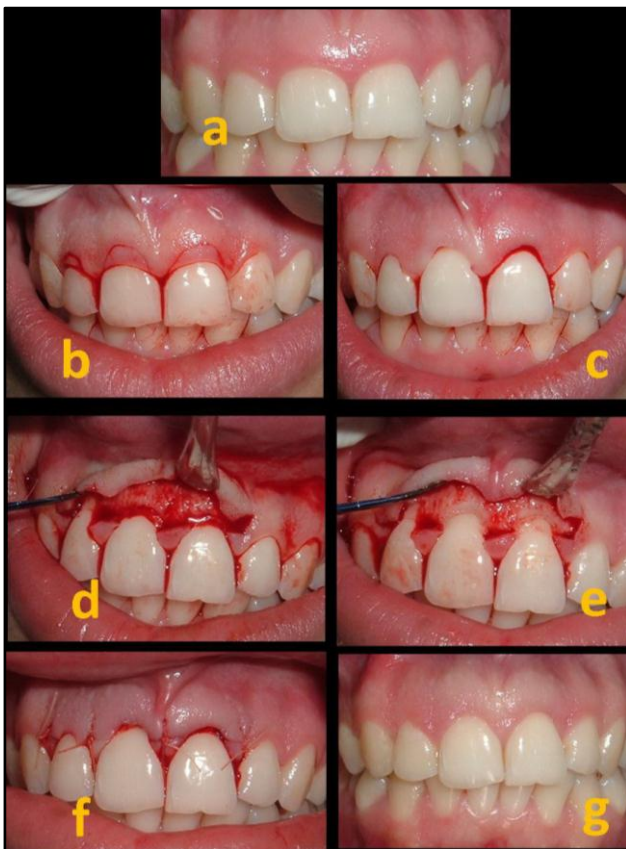


**Figure No.6:** Esthetic crown lengthening; (a) before, (b) after gingival excision, (c) evaluation of alveolar bone level, (d) vertical incisions to gain access for bone resection, (e) sutures for vertical incisions, (f) eight weeks post-op.

Another option is to use horizontal incisions to preserve the papilla; this is done by connecting the mesial and distal line angles of the adjacent teeth with horizontal incisions and without separating the tip of papilla from underlying bone (Figure 7).

After raising the full-thickness flap, bone resection could be done using burs or chisels. Specially designed end cutting burs are also available for crown lengthening procedures.<sup>6</sup> Such power-driven resection should be conducted with saline irrigation to prevent overheating the bone and to rinse away the remnants. Fine sutures such as 5-0 or 6-0 sutures are preferred to allow better healing and would be less disturbing to the patient for the next week until suture removal (Figure 6e). It is crucial to give proper instructions to patients to avoid any unwanted movement of the tissues

during the healing phase. In most cases, no antibiotic prophylaxis would be needed; and pain can be sufficiently controlled by oral administration of non-steroidal anti-inflammatory drugs. Since gingivectomy/gingivoplasty surgeries heal by secondary intention, more post-operative pain is expected, compared to apically positioned flaps. Although surgeries that include osseous resection have more post-operative pain, patients' discomfort levels associated with these different surgical techniques may show no statistical difference.<sup>8</sup>



**Figure No.7:** Esthetic crown lengthening; (a) before, (b+c) gingival excision, (d) alveolar bone exposure, (e) after bone resection, (f) sutures, (g) four weeks post-op.

## DISCUSSION

Since esthetic crown lengthening surgeries are elective procedures that aim to improve the appearance of the teeth and gums, the candidates should only receive such treatment if they believe that such a change will make them

more satisfied. However, the expectations of such patients need to be realistic. The clinician should make it clear that crown lengthening surgery for sound teeth is limited by a certain length of teeth, which cannot be exceeded.<sup>2,3</sup> Some excessive gingival displays, caused by a very high lip-line, would not be solved by crown lengthening and may need a lip repositioning surgery or even an orthognathic surgery.<sup>9</sup> Other considerations for bone resection should be the crown to root ratio; excessive osseous resection or attachment loss may risk the attachment of the tooth especially in teeth with periapical lesions or previous apicectomy.<sup>6</sup> Even though it is usually not an issue, the new gingival margin should not extend apically up to, or beyond, the mucogingival junction (Figure 3b).

## CONCLUSION

It is recommended that clinicians need to evaluate each case individually to figure out if crown lengthening is the proper therapeutic option. The selection of the appropriate technique depends on the clinician's personal preference and experience. Still, the clinician should be familiar with all different techniques, and be able to change or modify the surgical procedure when necessary.

## REFERENCES

1. Kokich VO Jr, Kiyak HA, Shapiro PA. Comparing the perception of dentists and lay people to altered dental esthetics. *J Esthet Dent* 1999;11(6):311-24.
2. Allen EP. Use of mucogingival surgical procedures to enhance esthetics. *Dent Clin North Am* 1988 Apr;32(2):307-30.
3. Magne P, Gallucci GO, Belser UC. Anatomic crown width/length ratios of unworn and worn maxillary teeth in white subjects. *J Prosthet Dent* 2003 May;89(5):453-61.
4. Ingber JS, Rose LF, Coslet JG. The "biologic width" - a concept in periodontics and

- restorative dentistry. *Alpha Omegan* 1977 Dec;70(3):62-5.
5. Lee EA. Aesthetic crown lengthening: classification, biologic rationale, and treatment planning considerations. *Pract Proced Aesthet Dent* 2004 Nov-Dec;16(10):769-78.
  6. Padbury A Jr, Eber R, Wang HL. Interactions between the gingiva and the margin of restorations. *J Clin Periodontol* 2003 May;30(5):379-85.
  7. Cortellini P, Tonetti MS. A minimally invasive surgical technique with an enamel matrix derivative in the regenerative treatment of intra-bony defects: a novel approach to limit morbidity. *J Clin Periodontol* 2007 Jan;34(1):87-93.
  8. Canakçi CF, Canakçi V. Pain experienced by patients undergoing different periodontal therapies. *J Am Dent Assoc* 2007 Dec;138(12):1563-73.
  9. Sheth T, Shah S, Shah M, Shah E. Lip reposition surgery: A new call in periodontics. *Contemp Clin Dent* 2013 Jul;4(3):378-81.

Source of Support: Nil

Conflict of Interest: Nil